

CASE REPORT**Detecting Acute Myocardial Infarction in Times of COVID:
A Case Report**Hatice Şeyma Akça¹, Serdar Özdemir², Abdullah Algin³, Serkan Emre Eroğlu⁴**Authors Affiliation:**University of Health Sciences,
Ümraniye Education and
Research Hospital, Istanbul,
Turkey¹⁻⁴**Correspondence to:**Hatice eyma Akça,
drhaticeseyma_@hotmail.com**ABSTRACT**

We highlight the importance of effective triage in the time of the pandemic. A 46-year-old male patient applied to the emergency room with fever, cough for 4 days, respiratory distress for 2 days, and myalgia. There was no suspected contact history up to 14 days before the onset of symptoms. Vital signs and laboratory values other than troponin were normal. Troponin -I values were 0.281, 0.252, 0.566 ng/ml (<0.0262 ng/ml), respectively. In computed tomography, subpleural millimetric focal slightly ground glass densities were selected in the

right apical posterior section in the thorax. In the swab sample (PCR), covid-19 was considered negative. He was admitted to the cardiology service. A stent was placed in the patient who underwent angiography on the 5th day of hospitalization. There are nonspecific symptoms that can be seen in many diseases, and effective triage should be given importance.

Keywords

Pandemic, myocardial infarction, triage

INTRODUCTION

A previously unidentified viral pneumonia was detected in Wuhan, China, from December 31, 2019, to January 7, 2020. The causative coronavirus was named SARS-CoV-2 or Covid-19. After these dates, the virus spread all over the world and caused a pandemic. The first case of the pandemic was seen on March 11, 2020, in Turkey. ⁽¹⁾

The pandemic, which reached its peak level in late April, tended to decrease partially since late May in Turkey. The number of cases, which increased again on June 15, was between 1000-1500 per day until August 30. Although there is no significant increase or decrease since August 30, an average of 1500 cases are reported daily. ⁽¹⁾

AIM

In this case report, we aimed to show that patients with high suspicion in terms of covid-19 may have different diagnoses.

CASE REPORT

A 46-year-old male patient presented to the emergency room with fever and cough for 4 days, respiratory distress for 2 days and back pain. There were no suspected contact history up to 14 days before the onset of symptoms. There was no history of chronic disease. His general appearance was alert, awake, cooperative and oriented. Lung examination showed normal breathing

sounds, no rales or rhonchi. There was no tachypnea and no clinical findings such as sweating, confusion, or syncope. Other systemic examination findings were normal.

He was afebrile, with a pulse of 72 beats/minute, respiratory rate of 20 breaths/minute and oxygen saturation was 95% on room air. Electrocardiography had normal sinus rhythm (Figure.1). There was no change in ECG findings during follow-up. Pertinent laboratory findings included normal LFTs, glucose levels, creatinine, BUN and electrolytes. His CBC shows a white blood count of 9.12×10^3 u/l ($4-10 \times 10^3$ u/l), hemoglobin: 15.7g/dl (11-15 g/dl), platelet: 170u/l (100-400 u/l), neutrophil: 4.59×10^3 u/l ($2-7 \times 10^3$ u/l) and lymphocyte: $3.4(0.8-4 \times 10^3$ u/l). Other important inflammatory makers such as CRP: 0.2mg/dl (0-0.5 mg/dl) and serial troponin -I values were 0.281, 0.252, 0.566 ng/ml (<0.0262 ng/ml) respectively. In computed tomography, subpleural millimetric focal slightly ground glass densities were seen in the right apical posterior section in the thorax and in the lateral section, in the bilateral posterobasal segments, and in the left apicoposterior segment (Figure.2). In the PCR (polymerase chain reaction) test taken twice for covid-19 was negative. I

The height of troponin was evaluated in favor of myocardial infarction. He was admitted to

the cardiology service. A stent was placed in the patient who underwent angiography on the 5th day of hospitalization. Stenosis was detected in the proximal circumflex artery in the patient, and angiography was successfully completed by placing a stent on the 5th day of hospitalization with percutaneous coronary intervention. The patient, who was started on acetylsalicylic acid, clopidogrel, and angiotensin converting enzyme inhibitor treatment, was discharged on the 7th day of hospitalization as no complications developed and his complaints regressed.

DISCUSSION AND CONCLUSION

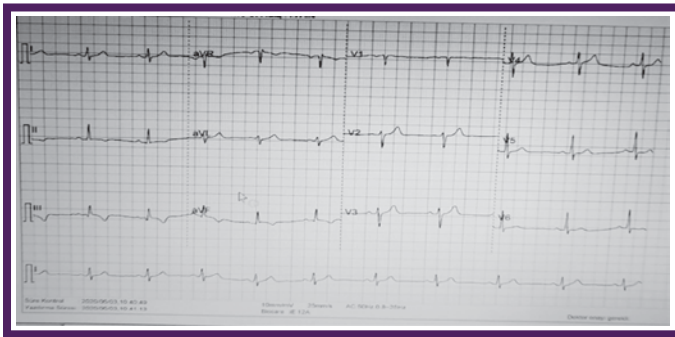

Figure.1 ECG findings of the patient at the first hospital admission

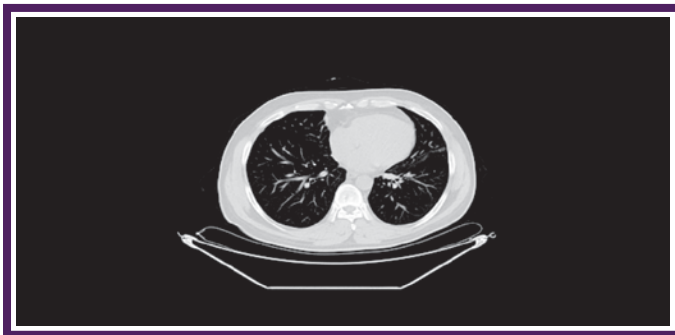


Figure.2 Fibrosis in the left apical segment

During the pandemic, an effective triage is one of the duties that fall on to the shoulders of the emergency departments but sometimes the symptoms can lead you to a number of different diagnoses. It has been reported in studies that mortality with Covid-19 is higher in advanced age, male patients, patients with additional diseases such as hypertension, diabetes mellitus, and coronary disease ⁽²⁾. The data and symptoms from China are listed in order of frequency; pneumonia, sore throat, fever, myalgia, nausea, vomiting, nasal congestion, diarrhea, chest pain ⁽³⁾. Reduction in smell and taste ⁽⁴⁾, headache, cloudiness, neurological symptoms ⁽⁵⁾ accompanied by developing the cerebrovascular disease, ⁽⁵⁾ dermatological symptoms accompanied by rash or

paleness ⁽⁶⁾ and, of course, psychiatric disorders, ⁽⁷⁾ were reported with case reports and studies. Symptoms of all branches of medicine, along with surgical symptoms, were visible ⁽⁸⁾. Since our patient had a complaint of cough and back pain, it was considered that the patient at high risk in terms of covid 19, and required investigations were requested. Since a large number of tomography reports discussed bilateral appearance of interstitial infiltrates specific to COVID, our tomography finding increased the suspicion that made us think of the possibility of covid 19 ⁽⁹⁾. In addition, non-specific tomography findings could be confused with different atypical pneumonia or chronic changes. In respiratory distress syndrome, it has been observed that thrombotic processes are also present along with the direct effect of the virus on the lung. Multiple organ thromboses were detected in the autopsy series. Thrombotic events with Covid-19 infection are known to be present and even cause death ⁽¹⁰⁾. Although our patient presented with symptoms of covid-19, he was diagnosed with myocardial infarction. The patient, who was found to be negative as a result of the swab (PCR), was admitted to the cardiology service because of the high troponin-I value and was treated subsequently. It can be argued that coronary artery thrombosis could be a subsequent event from COVID-19 but ongoing research needs to clarify the rate of thrombotic events with COVID-19. We know the importance of early covid 19 diagnoses during the pandemic. However, it should not be forgotten that there are nonspecific symptoms that can be seen in many diseases, and effective triage should be given due importance.

REFERENCES

1. Republic of Turkey Ministry of Health. Covid-19 Information page. Available from: https://covid19bilgi.saglik.gov.tr/depo/rehberler/COVID-19_Rehberi.pdf / [Accessed 14th October 2020].
2. Usuzaki T, Chiba S, Shimoyama M. How can we evaluate an interrelation of symptoms? *Archives of gerontology and geriatrics*. 2020; 89:104096. doi: 10.1016/j.archger.2020.104096
3. Gaythorpe K, Imai N, Cuomo-Dannenburg G, Baguelin M, Bhatia S, Boonyasiri A et al. *Symptom progression of COVID-19*. Imperial College London. Report number: 8, 2020. <https://doi.org/10.25561/77344>.
4. Menni C, Valdes AM, Freidin MB, Sudre CH, Nguyen LH, Drew DA et al. Real-time tracking of self-reported symptoms to predict potential COVID-19. *Nature medicine*. 2020; 26: 1037-40. <https://doi.org/10.1038/s41591-020-0916-2>
5. Wang HY, Li XL, Yan ZR, Sun XP, Han J, Zhang BW. Potential neurological symptoms of COVID-19.

Therapeutic Advances in Neurological Disorders. 2020; 13: 1756286420917830. doi:[10.1177/1756286420917830](https://doi.org/10.1177/1756286420917830)

6. Gupta G, Singh Y, Chellappan DK, Dua K. New emerging dermatological symptoms in coronavirus pandemic. *Journal of Cosmetic Dermatology.* 2020;19(9): 2447-8. Doi:10.1111/jocd.13466

7. Rohde C, Jepsen OH, Noerremark B, Danielsen AA. Psychiatric symptoms related to the COVID-19 pandemic. *Acta Neuropsychiatrica.*2020;32(5):2746. Doi: 10.1101/2020.04.16.20067744.olmayabilir.

8. Unal E, Yuksekdog S, Akca HS, Yildiz A. Latest warnings to surgeons taking care of patients with

COVID-19: a comparably successful experience from Istanbul. *Journal of Infectious Diseases & Travel Medicine.* 2020;4(1):000136. Doi: 10.23880/jidtm-16000136.

9. Rogalska-Płońska M, Kuźmierz A, Łapiński TW, Flisiak R, Computed tomography changes in lungs of COVID-19 patients. *Polish Archives of Internal Medicine.* 2020;130(6):541-3. Doi: 10.20452/pamw.15363.

10. Oudkerk M, Büller HR, Kuijpers D, Es NV, Oudkerk SF, Mcloud T et al. Thromboembolic complications in COVID-19: report of the National Institute for Public Health of the Netherlands. *Radiology.* 2020;297(1):216-22. Doi:10.1148/radiol.2020201629.

* ————— *