

NARRATIVE REVIEW

Thoracic Air Leak Syndrome in COVID-19 Patients: An Emergent Complication

Authors Affiliation:

1430 Tulane Ave, New Orleans, LA-70112, US,¹

Larkin Community Hospital, South Miami, FL - 33143, US,²

Correspondence to:

Emad Kandil
ekandil@tulane.edu

Ruhul Munshi¹, Samia Jahan², Mohammad Hussein¹, Eman Toraih¹, Emad Kandil¹

ABSTRACT**BACKGROUND**

Sudden clinical deterioration in coronavirus disease 2019 (COVID 19) patients may be caused by thoracic air leaks. In this review, we aimed to identify the risk factors predisposing to the development of alveolar air leak and outcomes in COVID 19 patients.

METHOD

Analysis of 33 studies of COVID - 19 who developed air leaks, published between April 20 to Aug 27, 2020, reviewed. Result Twenty-one females (16.8%) and 104 males (83.2%) were included in this study. Their median age was 44.75 years, ranging from 27.5 to 60.0. Of the 125 patients, 100(80%) developed Spontaneous pneumothorax, 47 (37.6%) had pneumomediastinum, and 37 (29.6%) presented with subcutaneous emphysema. A chest tube was inserted in 63 (50.4%) patients, 97 (77.6%) received

supplemental oxygen, 56 (44.8%) required mechanical ventilation, 64 (51.2%) were admitted to the Intensive Care Unit (ICU), 42 (33.6%) were admitted to the floor, and 35(28%) developed acute respiratory distress syndrome. The median length of hospital stay was 12 days (interquartile range=5.6-17.25), 57 (45.6%), patients were discharged with a median length of stay of 9 days (5.25-16.5), while mortality was reported in 29 patients (23.2%) after a longer hospitalization of 15 days (6.0-18.0). Of those who expired, only one was a smoker, and another had chronic obstructive pulmonary disease.

CONCLUSION

In COVID-19 disease, air leaks may cause potentially fatal outcomes even in formally stabilized non-smoker patients. Therefore, physicians should be aware of the development of occult air leak disease in rapidly deteriorating cohorts.

INTRODUCTION

Due to the heterogeneity of clinical presentation and complications, physicians faced overwhelming challenges during the coronavirus disease 2019 (COVID-19) epidemic due to the heterogeneity of clinical expression and complications⁽¹⁾. Clinical presentation varies from asymptomatic, mild/moderate, severe, and even death. Mild/moderate symptoms include generalized body ache, headache, fever, tiredness, and cough. Severe COVID 19 patients can be predicted if they have shortness of breath, chest pain while breathing, tachypnea, cyanosis of the face and lips, and new-onset confusion. Severe COVID 19 patients may develop acute respiratory distress syndrome. This acute respiratory distress syndrome may result in severe complications like air leak syndrome⁽²⁾. Due to exudative effusion in acute respiratory distress syndrome, thickened lung tissue makes the lung challenging to exchange gas; sustained-pressure ventilation requirement may lead to air leak syndrome⁽³⁾. One of the reasons for sudden clinical deterioration in COVID-19 patients is thoracic air leak syndrome⁽⁴⁾. It

is defined as the presence of extra-alveolar air in the thoracic spaces and includes spontaneous pneumothorax, pneumomediastinum, pneumopericardium, subcutaneous emphysema and interstitial emphysema⁽⁵⁾. Unravelling the clinical features of these patients would increase awareness of such complications. Herein, we systematically reviewed all COVID-19-related articles with patients presented with air leak syndrome to identify independent risk factors for its development and explore its prognosis in COVID-19 patients. We hypothesized that smoking and preexisting pulmonary diseases would accelerate the risk of developing air leak syndrome and synergistically enhance poor prognosis.

METHODS

Upon a comprehensive literature review in Web of Science (N=108), Embase (N=186), PubMed (N=260), and ScienceDirect (N=245) up to August 2020. Search terms were (pneumothorax OR pneumomediastinum OR subcutaneous emphysema) combined with (COVID-19 OR coronavirus disease

2019 OR severe acute respiratory syndrome coronavirus 2 OR SARS CoV-2). No time or language restriction was applied. Inclusion criteria were (1) Study design: peer-reviewed article of any type; (2) Population: confirmed COVID-19 patient; (3) Exposure: diagnosed clinically or radiologically with spontaneous pneumothorax, pneumomediastinum, pneumopericardium, subcutaneous emphysema or interstitial emphysema; (4) Outcome: mortality, length of stay, or complications. While in vitro and in vivo studies were excluded, data were abstracted in a predesigned excel sheet.

Clinical characteristics and outcomes were reported as frequency and percentage. Quantitative data were non-parametric and thus were reported as the median and interquartile range (IQR). Due to lacking enough data, quantitative synthesis meta-analysis was not feasible, and each patient's results within each study were pooled. P-value was set significant at <0.05. Statistical analysis was performed using SPSS v27.0, and the plot was generated using STATA v16.0.

RESULTS

Thirty-three included articles were published between April 20 and August 27, 2020, and reported from 13 countries, mainly China, the USA, and the UK (Table 1). The analysis included the characteristics of 125 COVID-19 patients who developed air leak syndrome. Their median age was 44.75 years (IQR=27.25-60). Twenty-one females (16.8%) and 104 males (83.2%) were included in this review (Table 2). Of the 125 patients, 100 (80%) developed spontaneous pneumothorax, 47 (37.6%) had pneumomediastinum, and 37 (29.6%) presented with subcutaneous emphysema. Only 20.8% were smokers. Based on our findings, hypertension (20%) followed by diabetes (14.4%), asthma (11.2%), and chronic obstructive pulmonary disease (COPD, 7.2%) were the comorbidities reported. Apart from the

high alanine transaminases reported in only two studies, no remarkable findings were found in the laboratory results.

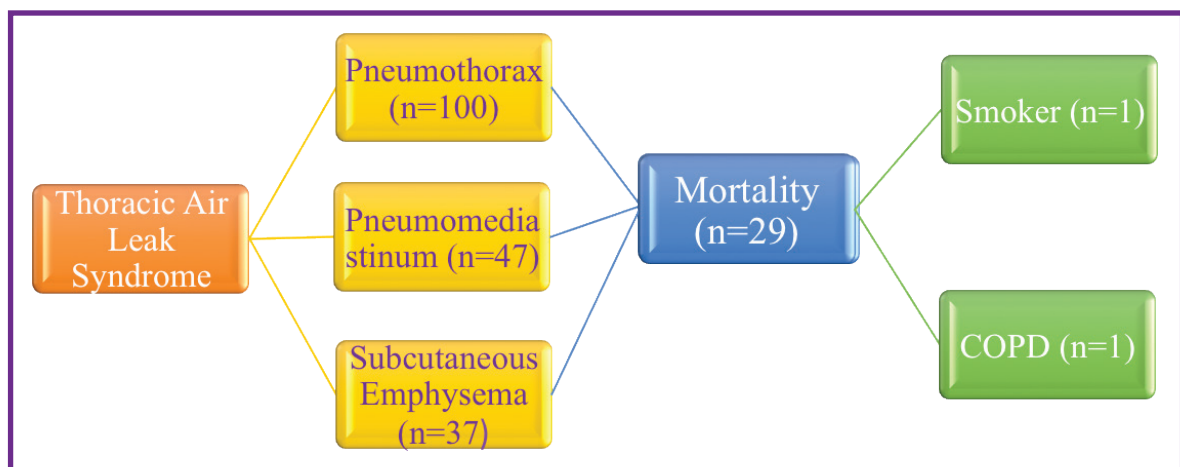
Nearly 28% of patients developed acute respiratory distress syndrome (ARDS). Around 77.6% of the cohort required oxygen therapy, and 44.8% were mechanically ventilated. Intensive Care Unit admission (ICU) was needed in 51.2% of patients, and mortality was reported in 36%. The median length of hospital stay was 12 days (5.6-17.5); specifically, nine days (5.25-16.5) for those who recovered and 15 days (6.0-18.0) among expired patients.

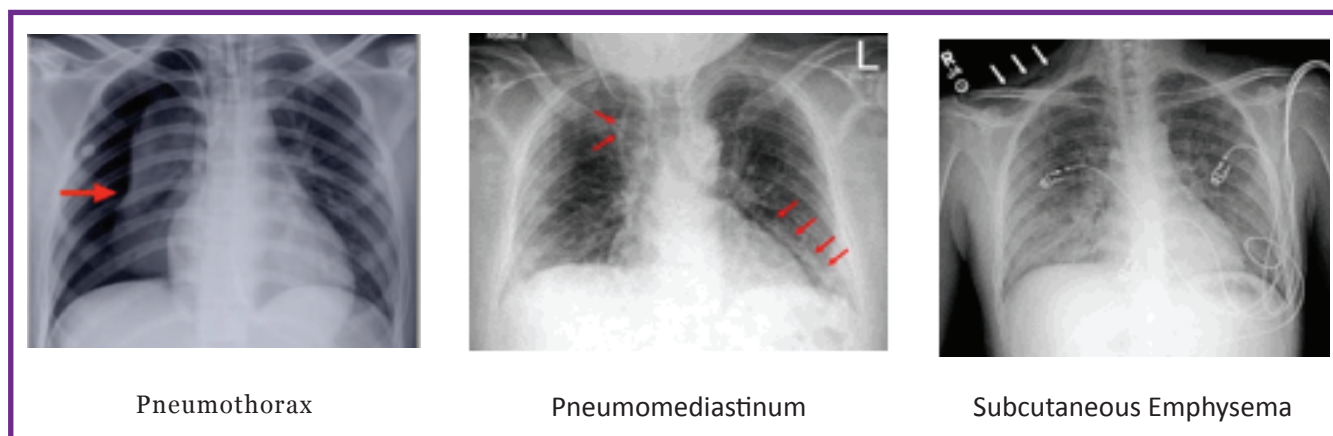
Of those who died (N=29), only one was a smoker, and another had COPD. Some non- survivors developed coincident ARDS (N=6) and shock (N=6) during the hospitalization period, and 64 patients were admitted to the ICU.

DISCUSSION

This study combines evidence from multi-institutional centers for healthcare policymakers to raise awareness about the elevating number of reported thoracic air leak syndrome in COVID 19 patients across different countries.

Air leak syndrome, consisting of pneumothorax, pneumomediastinum, and subcutaneous emphysema, is caused by an increase in the intra-alveolar pressure with subsequent alveolar rupture, air leak, with the possibility of lung collapse and impairment of oxygenation. Alveolar air leaks might be spontaneous (primary or secondary), traumatic, or iatrogenic, with spontaneous pneumothorax being the most common type⁽¹⁵⁾. Spontaneous air leak is a rare disease that commonly occurs in males between 10 to 30 years old and is rarely seen over 40. Smoking increases the risk of primary spontaneous pneumothorax twenty times in men. Smoking is one of the main triggering factors for the development of





subpleural bullae. Inflammation of these bullae might obstruct the small airways, leading to excessive intra-alveolar pressure, alveolar rupture, and subsequent air leak into the interstitium⁽³⁷⁾. Secondary spontaneous pneumothorax commonly develops in patients suffering from lung diseases such as pneumonia, chronic obstructive pulmonary disease, asthma, and lung cancer⁽³⁷⁾. In addition, it is a frequent complication in patients with ARDS, caused by pressure and volume-related alveolar rupture⁽³⁸⁾. While iatrogenic pneumothorax is commonly caused during an endoscopic procedure or following intubation and mechanical ventilation⁽³⁹⁾.

In the current analysis, the prevalence of air leaks was five times higher in male COVID-19 patients compared to females. Their median age was over 45 years. Only 20.8% of patients were smokers, 11.2% were asthmatics, and 7.2% had COPD. There was no other pre-existing pulmonary disease or reported history of recent trauma. Around 42.4% of patients were admitted with air leaks, and 20% developed air leaks throughout the hospital course before receiving any ventilation support. 37.6% of patients have air leaks after mechanical ventilation, either invasive or non-invasive. Of the patients who died, 23.2% were found to have either pneumothorax, pneumomediastinum, or subcutaneous emphysema. Only one patient had pre-existing COPD, and another one was a smoker, so air leak syndrome in COVID-19 patients can cause severe outcomes even without pre-existing pulmonary comorbidities.

Our findings were consistent with published articles that showed higher air leak syndrome incidence among males⁽³⁶⁾. Other studies reported the development of air leaks in non-intubated COVID-19 patients during hospitalization⁽⁴⁰⁾. However, others reported pneumothorax development in 5.9% of patients while on mechanical ventilation⁽⁴¹⁾. Joshi et al. reported that the incidence

of alveolar air leak was found to be 2.39%, with a mortality rate of 60%⁽⁴²⁾.

Even though the mechanism of the injury is not fully understood, multiple mechanisms are suggested. In addition to the ventilator-induced barotrauma among mechanically ventilated patients, COVID-19 infection could cause an inflammatory response with additional positive pressure ventilation. Persistent cough with severe intrapulmonary strain, increased respiratory effort, injury from activated inflammatory processes, cytokine storm and exudate accumulation, and ischemic lung parenchymal injury might promote pulmonary cystic lesions within the lungs. Our analysis determined no apparent risk factors, and there was a lack of autopsy findings to delineate the etiology of pathophysiological alterations of developing such complications in our study.

We could not identify predictor risk factors for mortality in such cohorts from the collected data. There was a lack of information that could unleash putative etiology for developing air leak syndrome. Therefore, further in-depth pathological and molecular analysis of deceased COVID-19 patients with similar presentations are recommended. This would be crucial to help countries design more effective interventions to shield vulnerable groups and reduce mortality risk.

Across the 33 eligible articles, 125 cases were recruited. Despite a limited sample size, they represented findings from multiple institutions reported in 13 countries. Most of the studies were case reports, and the available data described the presentation and outcomes at an individual level. Therefore, pairwise comparisons between patients of different presentations and associated with comorbidities were not feasible. Further additional studies are warranted to explore the etiology underlying the development of air leak syndrome in COVID-19 patients.

Author (ref)	Country of authors	Date of Publication	Study design	Sample size
Sun, R et al ⁶	China	03/2020	Case report	1
Changyu, Z et al ⁷	China	03/2020	Case report	1
Wang, W et al ⁴	China	04/2020	Clinical pearl	1
Wang, J et al ⁸	China	04/2020	Research Letter	1
Rohailla, S. et al ⁹	Canada	04/2020	Case report	1
Aioffi, A. et al ³	Italy	04/2020	Case report	2
Lacroix, M. et al ¹⁰	France	05/2020	Case report	1
Mohan, V et al ¹¹	USA	05/2020	Case report	1
Xiang, C et al ¹²	China	05/2020	Case report	1
Flower, L et al ¹³	UK	05/2020	Case report	1
Kolani, S. et al ¹⁴	Morocco	05/2020	Case report	1
Ucpinar, B et al ¹⁵	Turkey	05/2020	Case report	1
Spirio, JE et al ¹⁶	Germany	06/2020	Case report	1
Consoli, L et al ¹⁷	Italy	06/2020	Case report	1
Hollingshead, C et al ¹⁸	USA	06/2020	Case report	1
Vega, J et al ¹⁹	Spain	06/2020	Case report	3
Suwanwongse, K et al ²⁰	USA	06/2020	Research letter	4
Romano, N et al ²¹	Italy	06/2020	Case report	2
Wali, A. et al ²²	UK	06/2020	Case report	5
Gurkan, O et al ²³	Turkey	07/2020	Case report	1
Long, A et al ²⁴	USA	07/2020	Case report	1
González-Pacheco, H et al ²⁵	Mexico	07/2020	Case report	1
Collercandy, N et al ²⁶	France	07/2020	Case report	1
Janssen, J et al ²⁷	Netherlands	07/2020	Case report	1
Mallick, T et al ²⁸	USA	07/2020	Case report	3
Goldman, N et al ²⁹	UK	07/2020	Case report	1
Do Lago, V et al ³⁰	Brazil	07/2020	Research letter	2
Al-Shokri, S. et al ³¹	Qatar	07/2020	Case report	3
Al-Azzawi, M. et al ³²	USA	07/2020	Case report	3
Pooni, R et al ³³	UK	07/2020	Case report	1
Volpi, S. et al ³⁴	UK	08/2020	Case report	3
Janssen, M. et al ³⁵	Netherlands	08/2020	Case report	3
Martinelli, A et al ³⁶	UK	08/2020	Case series	71

Table 1. Characteristics of Included Articles

Characteristics	Levels	Frequency or Measure
Demographic data		
Age	In years	44.75 (27.25-60)
Sex	Male	104(83.2)
	Female	21(16.8)
Smoking	Positive	26(20.8)
Presentation		
Chest radiograph (CXR/CT)	Pneumothorax	100(80)
	Subcutaneous emphysema	37(29.6)
	Pneumomediastinum	47(37.6)
Comorbidities	Hypertension	25(20)
	Diabetes	18(14.4)
	Chronic obstructive pulmonary disease	9(7.2)
	Asthma	14(11.2)
Investigations		
Blood gas analysis	pH	7.44 (7.32-7.48)
	PCO ₂ (mmHg)	31.6 (24.4-38.4)
Laboratory data	Hb (g/dl)	12.7 (11.8-14.45)
	WBC (x10 ⁹ /L)	11.65 (8.25-17.25)
	Neutrophils (x10 ⁹ /L)	8.61 (5.6-11.85)
	Lymphocytes (x10 ⁹ /L)	1.32 (0.80-1.82)
	Platelet (x10 ⁹ /L)	229 (166-507.5)
	Alanine transaminases (IU/L)	107 (59.5-183)
	D-Dimer (mcg/ml)	1.75 (0.73-4.09)
	C-reactive protein (mg/dl)	12.65 (5.19-21.81)
Treatment		
COVID-19 medications	Hydroxychloroquine	8(6.4)
	Azithromycin	7(5.6)
	Tocilizumab	1(0.8)
	Intravenous steroids	4(3.2)
Intervention	Chest tube insertion	63(50.4)
	O ₂ therapy	97(77.6)
	Mechanical ventilation	56(44.8)
Disposition	Floor admission	42(33.6)
	Intensive Care Unit admission	64(51.2)
	N/A	19(15.2)

Continued

Characteristics	Levels	Frequency or Measure
Outcomes		
Complications	Pneumonia	4(3.2)
	Acute respiratory distress syndrome	35(28)
	Venous thromboembolism	1(0.8)
	Pulmonary embolism	1(0.8)
	Shock	6(4.8)
	Heart failure	1(0.8)
Fate	Discharge	57(45.6)
	Died	29(23.2)
	Not given	39(31.2)
Hospital length of stay, days	Overall patients	12 (5.6-17.25)
	Discharged patients	9.0 (5.25-16.5)
	Expired patients	15.0 (6.0-18.0)

Table 2. Characteristics of thoracic air leak syndrome in patients (N=125).

Data is presented as number and percentage or median and interquartile range (Q1-Q3).

CONCLUSION

In COVID-19 disease, air leak syndrome may cause fatal outcomes even in formally stabilized non-smoking patients. Physicians should be aware of the development of occult air leak disease in rapidly deteriorating patients.

AUTHOR'S CONTRIBUTION

RM: Study design, data extraction, analysis, draft manuscript; SM: Data extraction; MH: plotting the figure, review the draft, final approval; ET: Data analysis, writing the second draft, final approval. EK: Final approval.

ACKNOWLEDGMENTS

A sincere appreciation to Loula Burton from Tulane's Research Proposal Development Office for her diligent editing and proofreading of this paper.

CONFLICTS OF INTEREST

The authors declare no conflict of interest.

FUNDING

None.

REFERENCES

- Li Q, Guan X, Wu P, et al. Early Transmission Dynamics in Wuhan, China, of Novel Coronavirus-Infected Pneumonia. *New England Journal of Medicine*. 2020; 382(13):1199-1207.
- Munshi R, Hussein MH, Toraih EA, Elshazli RM, Jardak C, Sultana N, et al. Vitamin D insufficiency as a potential culprit in critical COVID-19 patients. *Journal of Medical Virology*. 2021; 93(2), 733-740.
- Aiolfi A, Biraghi T, Montisci A, et al. Management of persistent pneumothorax with thoracoscopy and bleb resection in COVID-19 patients. *The Annals of thoracic surgery*. 2020;110(5):e413-e415.
- Wang W, Gao R, Zheng Y, Jiang L. COVID-19 with spontaneous pneumothorax, pneumomediastinum and subcutaneous emphysema. *Journal of Travel Medicine*. 2020; 27(5): taaa062
- Smith J, Schumacher RE, Donn SM, Sarkar S. Clinical course of symptomatic spontaneous pneumothorax in term and late preterm newborns: report from a large cohort. *American Journal of Perinatology*. 2011; 28(2):163-168.
- Sun R, Liu H, Wang X. Mediastinal Emphysema, Giant Bulla, and Pneumothorax Developed during the Course of COVID-19 Pneumonia. *Korean Journal of Radiology*. 2020; 21(5):541.
- Zhou C, Gao C, Xie Y, Xu M. COVID-19 with spontaneous pneumomediastinum. *The Lancet Infectious Diseases*. 2020; 20(4):510.
- Wang J, Su X, Zhang T, Zheng C. Spontaneous Pneumomediastinum: A Probable Unusual Complication of Coronavirus Disease 2019 (COVID-19) Pneumonia. *Korean Journal of Radiology*. 2020; 21(5):627.

9. Rohailla S, Ahmed N, Gough K. SARS-CoV-2 infection associated with spontaneous pneumothorax. *Canadian Medical Association Journal*. 2020; 192(19):E510.
10. Lacroix M, Graïess F, Monnier-Cholley L, Arrivé, L. SARS-CoV-2 pulmonary infection revealed by subcutaneous emphysema and pneumomediastinum. *Intensive Care Medicine*. 2020; 46 (8):1620–1621.
11. Mohan V, Tauseen RA. Spontaneous pneumomediastinum in COVID-19. *BMJ Case Reports CP*. 2020; 13(5):e236519.
12. Xiang C, Wu G. SARS-CoV-2 pneumonia with subcutaneous emphysema, mediastinal emphysema, and pneumothorax. *Medicine*. 2020; 99(20): e20208.
13. Flower L, Carter J-PL, Rosales Lopez J, Henry AM. Tension pneumothorax in a patient with COVID-19. *BMJ Case Reports*. 2020; 13(5): e235861.
14. Kolani S, Houari N, Haloua M, et al. Spontaneous pneumomediastinum occurring in the SARS- COV-2 infection. *ID Cases*. 2020; 21: e00806.
15. Ucpinar BA, Sahin C, Yanc U. Spontaneous pneumothorax and subcutaneous emphysema in COVID-19 patient: Case report. *Journal of Infection and Public Health*. 2020; 13(6):887-889.
16. Spiro JE, Sisovic S, Ockert B, Böcker W, Siebenbürger G. Secondary tension pneumothorax in a COVID-19 pneumonia patient: a case report. *Infection*. 2020; 48(6):941-944.
17. Consoli L, Bendotti V, Cicchinelli S, Gaioni F, Prandolini P, Bettonagli M, et al. 2019 novel coronavirus (COVID-19) pneumonia complications: the importance of lung ultrasound. *Journal of ultrasound*. 2020:1-4.
18. Hollingshead C, Hanrahan J. Spontaneous Pneumothorax Following COVID-19 Pneumonia. *ID Cases*. 2020; 21: e00868.
19. Vega JML, Gordo MLP, Tascón AD, Vélez SO. Pneumomediastinum and spontaneous pneumothorax as an extrapulmonary complication of COVID-19 disease. *Emergency radiology*. 2020; 27(6):727-730.
20. Suwanwongse K, Shabarek N. Pneumomediastinum in Mechanically Ventilated Coronavirus Disease 2019 Patients. *Journal of Cardiothoracic and Vascular Anesthesia*. 2021; 35(2):686-688.
21. Romano N, Fischetti A, Melani EF. Pneumomediastinum Related to Covid-19 Pneumonia. *The American Journal of the Medical Sciences*. 2020; 360(6): e19-e20.
22. Wali A, Rizzo V, Bille A, Routledge T, Chambers A. Pneumomediastinum following intubation in COVID-19 patients: a case series. *Anaesthesia*. 2020; 75(8):1076-1081.
23. Gurkan O, Yilmaz A, Cengel F, Altunok ES, Ekin EE. COVID-19 Pulmonary Infection with Pneumothorax in a Young Patient. *Journal of the College of Physicians and Surgeons Pakistan*. 2020; 30(6):43- 45.
24. Long A, Grimaldo F. Spontaneous hemopneumothorax in a patient with COVID-19. *The American Journal of Emergency Medicine*. 2021; 40:228. E221-228. E222.
25. González-Pacheco H, Gopar-Nieto R, Jiménez-Rodríguez G-M, Manzur-Sandoval D, Sandoval J, Arias-Mendoza A. Bilateral spontaneous pneumothorax in SARS-CoV-2 infection: a very rare, life-threatening complication. *The American Journal of Emergency Medicine*. 2021; 39: 258.e251- 258.e253.
26. Collercandy N, Guillon A. Pneumomediastinum in critically ill adult with COVID-19. *Medicina Intensiva*. 2020.
27. Janssen J, Kamps MJ, Joosten TM, Barten DG. Spontaneous pneumomediastinum in a male adult with COVID-19 pneumonia. *The American Journal of Emergency Medicine*. 2021; 40:228. e223- 228. E225.
28. Taha Mallick AD, Engdahl R, Sabado M. COVID-19 complicated by spontaneous pneumothorax. *Cureus*. 2020; 12(7).
29. Goldman N, Ketheeswaran B, Wilson H. COVID-19-associated pneumomediastinum. *Clinical Medicine*. 2020.
30. Do Lago VC, Cezare TJ, Fortaleza CMCB, Okoshi MP, Baldi BG, Tanni SE. Does COVID-19 increase the risk for spontaneous pneumothorax? *The American journal of the medical sciences*. 2020. 2020 Dec 1;360(6):735-7.
31. Al-Shokri SD, Ahmed AO, Saleh AO, Abou Kamar M, Ahmed K, Mohamed MF. Case Report: COVID-19–Related Pneumothorax—Case Series Highlighting a Significant Complication. *The American journal of tropical medicine and hygiene*. 2020; 103(3):1166-1169.
32. Al-Azzawi M, Douedi S, Alshami A, Al-Saoudi G, Mikhail J. Spontaneous subcutaneous emphysema and pneumomediastinum in COVID-19 patients: an indicator of poor prognosis? *The American Journal of Case Reports*. 2020; 21:e925557-925551.
33. Pooni R, Pandey G, Akbar S. Broadening the differential: pneumomediastinum and COVID-19 infection. *BMJ Case Reports CP*. 2020; 13(8):e237938.
34. Volpi S, Ali JM, Suleman A, Ahmed RN. Pneumomediastinum in COVID-19 patients: a case series of a rare complication. *European Journal of Cardio-Thoracic Surgery*. 2020; 58(3):646- 647.
35. Janssen ML, van Manen MJ, Cretier SE, Braunstahl G-J. Pneumothorax in patients with prior or current COVID-19 pneumonia. *Respiratory Medicine Case Reports*. 2020; 31:101187.
36. Martinelli AW, Ingle T, Newman J, et al. COVID-19 and pneumothorax: a multicentre retrospective case series. *European Respiratory Journal*. 2020; 56(5):2002697.
37. Sahn SA, Heffner JE. Spontaneous Pneumothorax. *New England Journal of Medicine*. 2000; 342(12):868-874.

38. Woodside KJ, van Sonnenberg E, Chon KS, Loran DB, Tocino IM, Zwischenberger JB. Pneumothorax in patients with acute respiratory distress syndrome: pathophysiology, detection, and treatment. *Journal of Intensive Care Medicine*. 2003 Jan;18(1):9-20.
39. Kouritas VK, Papagiannopoulos K, Lazaridis G, et al. Pneumomediastinum. *Journal of thoracic disease*. 2015; 7(Suppl 1): S44.
40. Eperjesiova B, Hart E, Shokr M, Sinha P, Ferguson GT. Spontaneous Pneumomediastinum/Pneumothorax in Patients With COVID-19. *Cureus*. 2020;12(7):e8996.
41. Yao W, Wang T, Jiang B, et al. Emergency tracheal intubation in 202 patients with COVID-19 in Wuhan, China: lessons learnt and international expert recommendations. *British journal of anaesthesia*. 2020 Jul 1;125(1):e28-37.
42. Sharad J, Ankit B, Nitesh T, Shailendra C, Ali S. Alveolar air leak syndrome a potential complication of COVID-19-ARDS-single center retrospective analysis. *Journal of the Association of Physicians of India*. 2021:22-26.